

## Verrucous Hemangioma: A Clinical Mimic of Verrucous Carcinoma

Poornima Vijayan, MD, Anupama Ponniah, MD, Babitha A.M, MD, Laila M. Ilias, MD

Address: Department of Pathology, MES Medical College, Perinthalmanna, Kerala

E-mail: poornima\_vij@yahoo.co.in

\* Corresponding Author: Dr. Poornima Vijayan, Department of Pathology, MES Medical College, Perinthalmanna, Kerala

Published:

J Turk Acad Dermatol 2016; 10 (3): 16103c7

This article is available from: <http://www.jtad.org/2016/3/jtad16103c7.pdf>

**Keywords:** Verrucous hemangioma, verrucous carcinoma, vascular malformation

### Abstract

**Observation:** Verrucous hemangioma is a rare congenital localized vascular malformation. It is commonly noted at birth or in early childhood, most often located on the lower extremities. This lesion is known for its recurrence because of extension into deep tissue. We report a case of verrucous hemangioma in a 56-year old lady who presented with a large rapidly recurring ulcero-proliferative growth involving the left thumb, which was clinically diagnosed as verrucous carcinoma. Because of the rapid recurrence of the lesion after the first excision, an amputation of the thumb had to be done in this patient. We present this case for its rarity and its inclusion in the differential diagnoses of many conditions including verrucous carcinoma.

### Introduction

Verrucous hemangioma is a rare vascular malformation which usually appears at birth or in childhood, enlarges and spreads in later life. It commonly occurs on the legs in the form of a bluish-red soft plaques and nodules which become warty as the lesion ages or following trauma. Because of their deep extension, complete excision may be difficult, with a high incidence of recurrence and satellite lesions [1, 2].

### Case Report

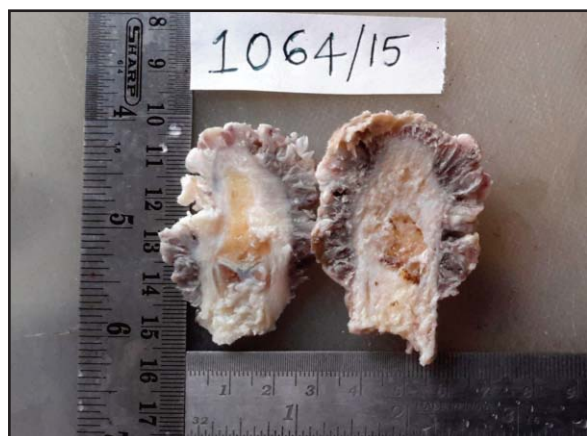A 56 year old lady presented to the surgical outpatient department with complaints of an ulcerated warty growth over her left thumb since 2 months. The patient gave a history of excision of the lesion from a different hospital with rapid recurrence of the lesion over a period of 1 week. The

clinical notes and histopathological reports of the previous excision were not available.

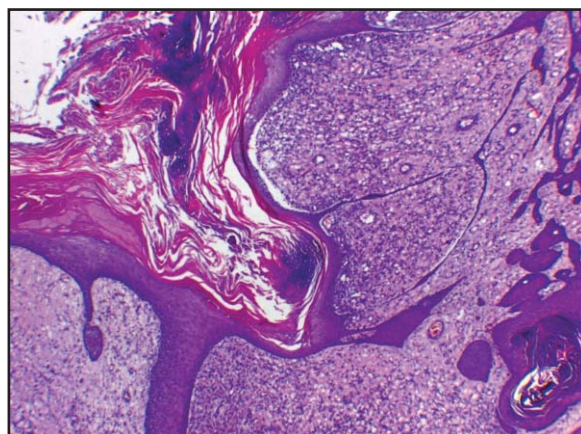
On clinical examination, a 7x4cm ulcero-proliferative growth was seen involving the whole distal phalanx of the left thumb. Slough and specks of hemorrhage were evident. The lesion bled to touch. A clinical diagnosis of verrucous carcinoma was entertained.

A wedge biopsy from the lesion was taken and sent to our department for histopathological examination. The histopathological examination of the lesional biopsy revealed marked ulceration of overlying epidermis with numerous capillary sized vessels in the superficial and deep dermis along with granulation tissue adjacent to the ulcerated area. It was reported as capillary hemangioma with ulceration.

Subsequently, the amputation specimen of the left thumb was sent for histopathological examination. On gross examination, a grey white verrucous lesion was seen mostly over the dorsal aspect of the left thumb, involving the distal and part of the



**Figure 1.** Amputation specimen of left thumb showing a verrucous growth



**Figure 2.** Epidermis with acanthosis, hyperkeratosis and papillomatosis, with superficial and deep dermis showing proliferation of capillary sized vessels. (4x&10x, H&E)

middle phalanx, measuring 7x4x1 cm. The resected margin was 1.5 cm away from the lesion (**Figure 1**).

Multiple sections were taken from the lesion and the resected margin. Sections examined revealed epidermis with papillomatosis, irregular acanthosis, hyperkeratosis and areas of ulceration. Superficial and deep dermis showed several capillary sized vessels lined by flattened to plump endothelial cells in a loose myxoid stroma. Occasional mitotic figures were noted. The lesion was seen in close proximity with the underlying bone. The resected margin was free (**Figures 2, 3 and 4**).

## Discussion

Verrucous hemangioma is a rare localized congenital vascular malformation, first described by *Halter* in 1937 and defined by *Loria et al* in 1958. The term 'verrucous hemangioma' was coined by *Imperial and Helwig* in 1967 [1]. It commonly presents at birth, in early childhood or even in adult life, and the commonest location is the lower extremities. Other locations include trunk, glans penis etc. The early clinical lesions of verrucous hemangioma are non-keratotic soft bluish-red in color. Over time they gradually enlarge and become hyperkeratotic and verrucous, usually following trauma or infection. In our case, the lesion presented as a large verrucous growth involving the left thumb in a 56 year old lady.

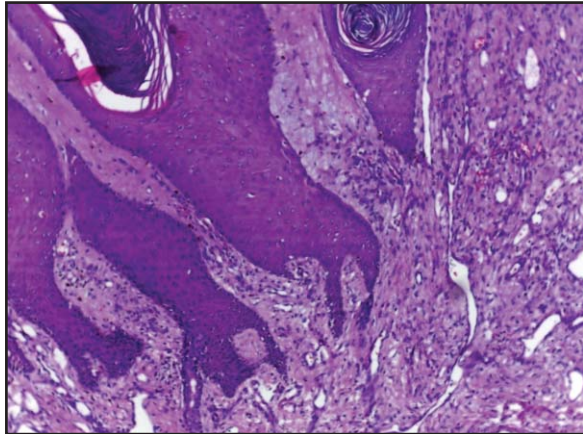
Clinically, these lesions can be misdiagnosed as angiokeratoma, verrucous epidermal

nevus, lymphangioma circumscriptum, squamous cell / verrucous carcinoma or even rarely malignant melanoma [3].

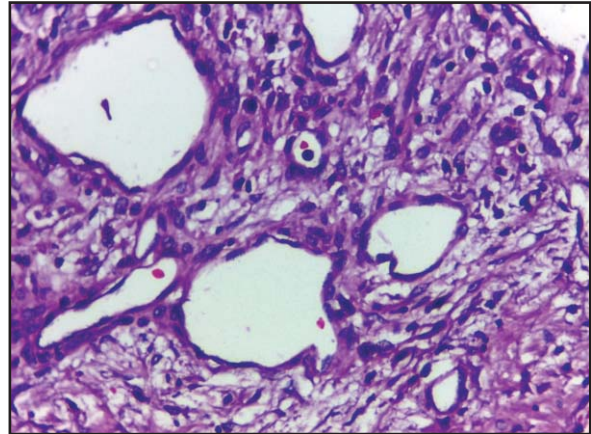
Verrucous hemangioma is a variant of capillary or cavernous hemangioma that causes the overlying skin to undergo reactive hyperkeratosis, acanthosis and papillomatosis, features that obscure the vascular nature of the lesion. Some authors regard these lesions as malformations. The vessels, a mixture of dilated capillaries and veins, involve the superficial and deep dermis and sometimes extend into the subcutis. Inflammation, hemosiderin laden macrophages and fibrosis may be present in the upper dermis [4]. Typical histopathological features were observed in our case also.

Immunohistochemical staining with endothelial markers like CD31, CD 34 and GLUT1 may be done for confirmation, but diagnosis can be made based on light microscopic features alone [5].

Early diagnosis is important to get a better cosmetic result. Recurrence is very common in verrucous hemangioma because of the involvement of deeper tissue and possibly because of altered hemodynamics opening up pre-existing non-canalized malformed vessels [1]. Verrucous hemangioma must be excised while still small to prevent unsightly scars. Surgical excision in combination with laser therapy is the preferred treatment for verrucous hemangioma because the crucial pathologic change is concentrated in the



**Figure 3.** Epidermis with acanthosis, hyperkeratosis and papillomatosis, with superficial and deep dermis showing proliferation of capillary sized vessels. (4x&10x, H&E)



**Figure 4.** Dermis showing capillary sized vessels lined by plump to flattened bland endothelial cells. (40x, H&E)

subcutaneous tissue. The use of clinical inspection, palpation, and imaging studies before surgery is helpful in delineating the underlying mass [6]. As with our case, the first excision with involved resected margin resulted in rapid recurrence of the lesion which then warranted an amputation of the thumb.

### Conclusion

We present this case for its sheer rarity of its occurrence and presentation, its inclusion in the differential diagnoses of the aforementioned conditions including verrucous carcinoma, its notoriety for recurrence and the need for excision with wide margins.

### References

1. Imperial R, Helwig EB. Verrucous haemangioma: a clinicopathological study of twenty one cases. Arch Dermatol 1967; 96: 247-253. PMID: 6038751

2. Yasar A, Ermertcan AT, Bilac C, Bayraktar DB, Temiz P, Ozturkcan S. Verrucous hemangioma. Indian J Dermatol Venerol Leprol 2009; 75: 528-530.
3. Pérez-Varela L, Del Pozo J, Pineyro F. Verrucous Hemangioma mimicking melanoma in an elderly man. Journal of Cosmetics, Dermatological Sciences and Applications 2011; 1: 153-156.
4. Calonje E. Vascular tumors: Tumors and tumor-like conditions of blood vessels and lymphatics. In: Lever's Histopathology of the Skin. Elder DE, Elenitsas R, Johnson BL, Murphy GF, Xu X, editors. 10th ed. Philadelphia: Lippincott Williams and Wilkins; 2009, 1007-1056.
5. Garrido-Ríos AA, Sánchez-Velicia L, Marino-Harrison JM, Torrero-Antón MV, Miranda-Romero A. A histopathologic and imaging study of Verrucous Hemangioma. Actas Dermosifiliogr 2008; 99: 723-726.
6. Yang CH, Ohara K. Successful surgical treatment of verrucous hemangioma: a combined approach. Dermatol Surg 2002; 28: 913-919. PMID: 12410675